

## Effect of bromadiolone on haematology, liver and kidney in *Mus musculus*

K. Revathi<sup>1</sup> and M. Yogananda<sup>2</sup>

<sup>1</sup>Department of Zoology, Ethiraj College for Women, Chennai-600 105 India

<sup>2</sup>PG and Research Department of Biotechnology and Microbiology, Al-Ameen City College, Bangalore-560 027, India

(Received: 9 January, 2004 ; Accepted: 22 July, 2004)

**Abstract:** Bromadiolone, a second generation anticoagulant rodenticide was tested on *Mus musculus* to evaluate its effects on blood, liver and kidney at varied time intervals of 6, 12, 24 and 48 hrs. Groups of six animals each were selected for experiment. Animals were administered with bromadiolone in the form of bait at 6, 12, 24 and 48 hrs time intervals. Control animals were maintained for each time interval. After each time interval the experiment and the control animals were sacrificed and the effect of bromadiolone on blood, liver and kidney were studied.

**Key words :** *Mus musculus*, Bromadiolone, Rodenticide.

### Introduction

The only practical and feasible method to bring down rodent population effectively over a large area is by the use of rodenticides. The uses of rodenticides have produced desirable effect in controlling rodents, but are quite toxic and contaminate the environment. Rodenticides are broadly classified as first generation and second generation rodenticides. The first generation rodenticides include quick acting acute poisons such as zinc phosphate and barium carbonate. Second generation rodenticides include slow acting multiple doses poisons such as rodfarin and rotafin anticoagulants.

Bromadiolone is second generation anticoagulant rodenticide. Efficiency of single dose treatment of bromadiolone against Indian rodents was studied. The studies showed 100% mortality in single dose of bromadiolone. The effect of bromadiolone on haematology and histology has not been studied. In this current study analysis of bromadiolone on rodents is studied considering that this chemical would probably enter the food chain. Also considering, this would ultimately effect the physiological mechanism in higher vertebrates.

The present study was carried out with the following objectives. Firstly, to evaluate the acute toxic effect of bromadiolone at different concentration. Secondly, to evaluate pathological effects at varied time intervals viz., 6, 12, 24 and 48 hrs. Finally, to find the changes that occurs in haematology, kidney and liver tissues. The test species selected for the above experiment is *Mus musculus*. The reason for selection is that, they possess many biochemical and physiological similarities with those of human beings.

### Materials and Methods

Wild type house mice *Mus musculus*, commonly available in the premises of Guindy, Chennai, Tamilnadu were procured from local animal supplier. The mice were screened for signs of diseases; physical damage etc. Only healthy animals were taken for the study. Male and female mice weighing 15 gram were separated and used for the study.

Animals were housed in wooden shoebox type cages, with one animal per cage. Food was provided in the form of pellet, supplied by Amruth feeds. Ordinary tap water treated in aquaguard water purifier was provided in bottle attached with sipper. Food and water was provided *ad libitum*. The animals were acclimatized for a week before start of the experiment.

The test substance bromadiolone is a second-generation anticoagulant and is commercially available under the trade name "Moosh Moosh". Its chemical formula is C<sub>30</sub> H<sub>23</sub> BrO<sub>4</sub>, it is a greenish blue waxy cake. Bromadiolone wax cake is directly palatable to the test animal.

**Acute toxicity study:** Since 100% survivals of experimental animals were essential for the study, an acute toxicity study was conducted before the start of the experiment. The acute toxicity study was carried out by "no choice test method" to determine their level of tolerance (Mathur and Prakash, 1984).

The toxic impact of bromadiolone and the percentage of mortality were carried out on six animals. Animals after acclimatization were exposed to bromadiolone, until all the animals were killed by the action of the rodenticide bromadiolone (Table 1). The acute toxicity test proved that *Mus musculus* could survive for 48 hrs after consuming bromadiolone.

**Oral toxicity study:** Further, new batches of animals were selected. The animals were divided into 5 groups of 6 animals each. Group 1 served as control. The animals were orally dosed with bromadiolone for a period of 6 hrs for G<sub>2</sub>, 12 hrs for G<sub>3</sub>, 24 hrs for G<sub>4</sub> and 48 hrs for G<sub>5</sub>. After the specific period of time interval, each group was sacrificed. The animals were euthanised under ether anesthesia; blood was collected in sterile heparinized vials by orbital sinus puncture. The animals were subjected to necropsy; liver and kidneys were collected. The weight of liver and kidneys were recorded from all the animals and the tissues were fixed in 10% Buffer neutral formalin for 48 hrs. The blood samples collected were subjected to haematological analysis for haemoglobin, RBC, WBC, DLC, and Platelet count. The tissues collected were subjected to histopathological examination.

### Results and Discussion

The acute toxic impact of the anticoagulant rodenticide Bromadiolone was obtained from the percentage mortality of the test animals indicated 100% survival upto 48 hrs. It showed 66% survival upto 72 hrs. 50% survival upto 96 hrs, 33% survival upto 120 hrs and none survived at 144 hrs. Since 100% survival of the animal was required for oral toxicity study, it was limited to 48 hrs. The behavioral changes were

also recorded. The animals exhibited marked changes such as lethargic and blood stain in excreta when compared with that of control.

Based on the results of acute toxicity study the time intervals for oral toxicity study were fixed as 6, 12, 24 and 48 hrs. At the end of each time interval the animals were subjected to necropsy, blood collection and tissue collection. The average consumption of bromadiolone was calculated for each animal.

**Table – 1:** Acute toxicity test of bromadiolone on *Mus musculus*.

Hours of exposure	Consumption of bait g	Average dose ingested mg/kg	Total no of animals	Alive	Dead
6	0.80	2.69	6	6	–
12	1.60	5.38	6	6	–
24	3.63	12.09	6	6	–
48	3.75	12.49	6	6	–
72	4.00	13.33	6	4	2
96	4.16	13.86	4	3	1
120	4.18	13.93	3	2	1
144	4.22	14.06	2	-	2

**Table – 2:** Consolidate table showing average poison consumed and average weight of liver and kidney in *Mus musculus* after exposure to bromadiolone.

Parameters	Average poison consumed (mg/kg)	Weight of kidney (mg)	Weight of liver (mg)
Control	-	100±0.5	533.66±24.67
06 hrs	2.693	106.83±1.36	553.83±2.2
12 hrs	5.388	115.66±1.59	568.83±3.15
24 hrs	12.098	125.33±3.70	575.00±1.00
48 hrs	12.526	133.66±5.72	578.00±2.5

All values are expressed in mean ±SD values for six animals.

**Table – 3:** Consolidated table showing average Hb% RBC, WBC & platelets count in *Mus musculus* after exposure to bromadiolone.

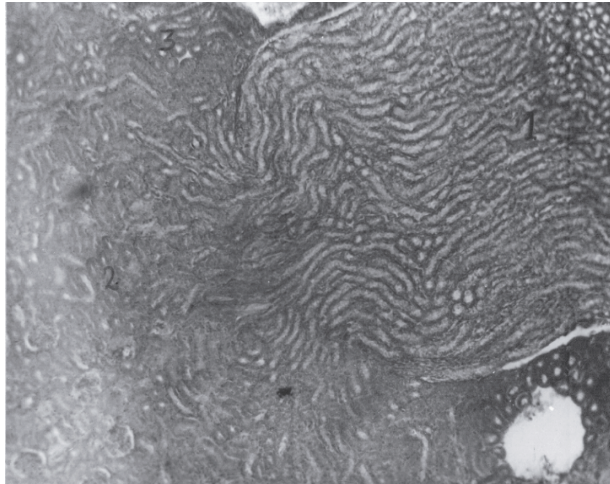
Parameters	APC*	Hb% mg/kg	RBC	WBC million mm <sup>3</sup>	Platelets thousand mm <sup>3</sup>
Control	—	84.58±0.40	4.26±0.17	6766±0.22	3.15±0.22
06 hrs	2.693	68.5±0.20	3.3±0.15	6808±0.16	2.90±0.09
12 hrs	5.388	74.25±1.04	3.42±0.12	7166±0.12	2.31±0.10
24 hrs	12.098	70.33±0.52	4.12±0.08	9583±0.20	2.21±0.10
48 hrs	12.526	77.5±0.51	4.20±0.11	8633±0.15	2.18±0.11

\* Average Poison Consumed. All values are expressed in mean ±SD values for six animals.

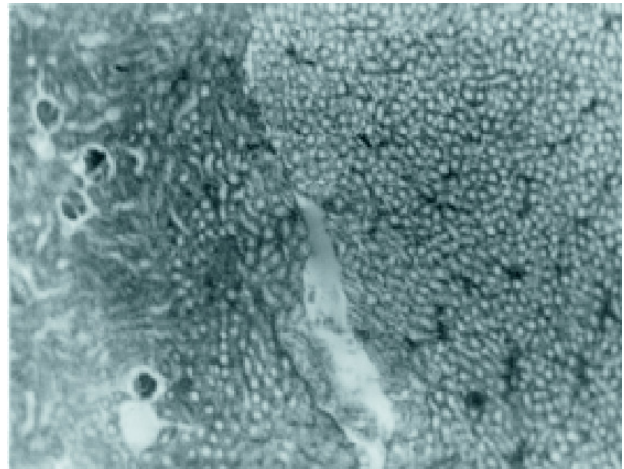
**Table – 4:** Consolidated table showing average Differential Leucocyte Count in percentage of *Mus musculus* after exposure to bromadiolone.

Parameters	Lymphocyte	Neutrophils	Monocyte	Eosinophil	Basophils
Control	60.31±0.90	33.58±0.50	2.55±0.10	3.06±0.26	0.48±0.07
06 hrs	65.00±0.81	31.0±0.81	1.4±0.17	1.90±0.07	0.63±0.04
12 hrs	71.58±0.92	24.50±0.50	1.75±0.22	1.96±0.26	0.25±0.05
24 hrs	63.95±0.30	30.08±0.28	2.68±0.43	2.95±0.07	0.46±0.10
48 hrs	63.83±0.70	30.60±0.28	2.08±0.14	2.90±0.20	0.50±0.20

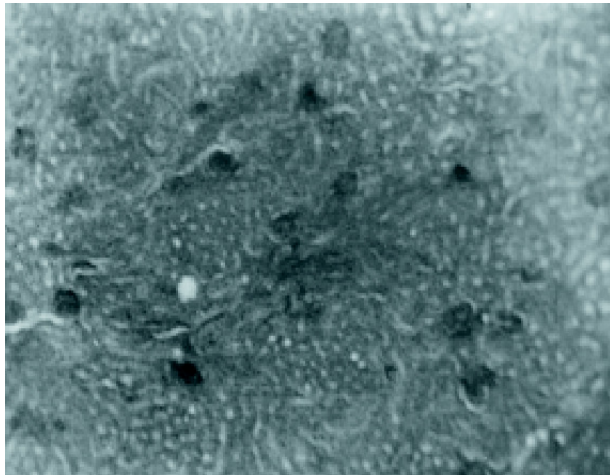
All values are expressed in mean ±SD values for six animals.



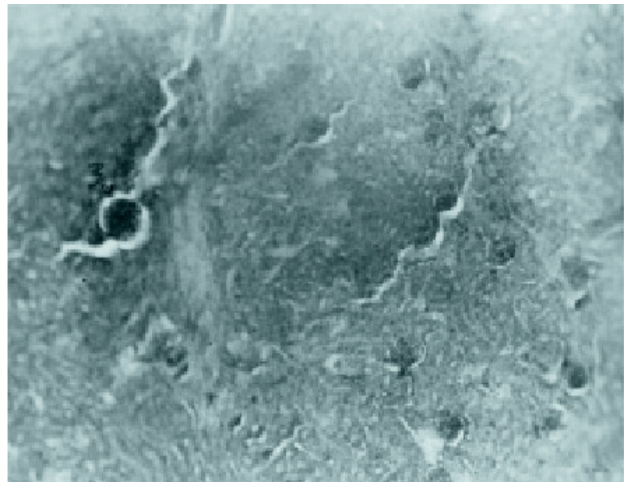
**Fig. 1:** Normal kidney.



**Fig. 2:** Kidney after 6 hours showing increased concentration of toxic debris.



**Fig. 3:** Kidney after 12 hours showing accumulation of toxic debris.



**Fig. 4:** Kidney after 24 hours showing necrosis, degeneration and accumulation of toxic debris.

A consolidated average poison consumption and average weights of kidney and liver of *Mus musculus* after the exposure to bromadiolone were taken for control, 6, 12, 24 and 48 hrs is shown in (Table 2). The effect of bromadiolone on the blood of *Mus musculus* is given in (Table 3).

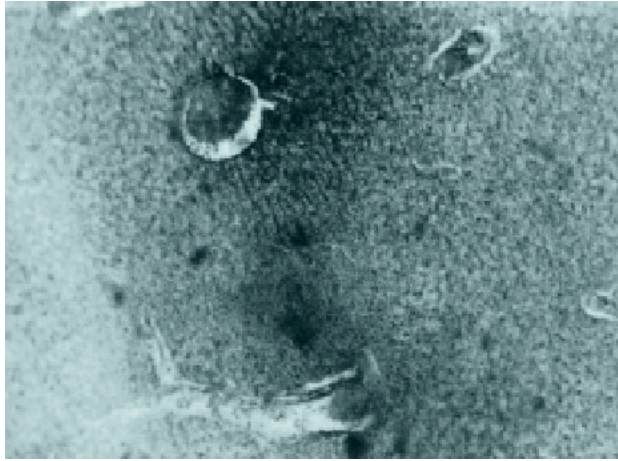
*Mus musculus* are capable of withstanding the anticoagulant rodenticide bromadiolone for 48 hrs after ingestion. At 48 hrs-dosing period the animals showed lethargic and blood stain in faeces. As the dosing period increased the death occurred and continued upto 144 hrs. None of the animals could survive after 144 hrs. Similar result was observed by (Scurgic and Cooke, 1979) in *Rana temporaria*. Lack of motility was observed by (Jwarez *et al.*, 1984) while they exposed the larvae of *Bufo averarum* to organochlorine insecticides.

In the oral toxicity study, at 6 hrs there was an increase in kidney and liver weight. This was statistically significant in kidney alone. Whereas incase of 12, 24 and 48 hrs, the weights were statistically analysed and both the liver

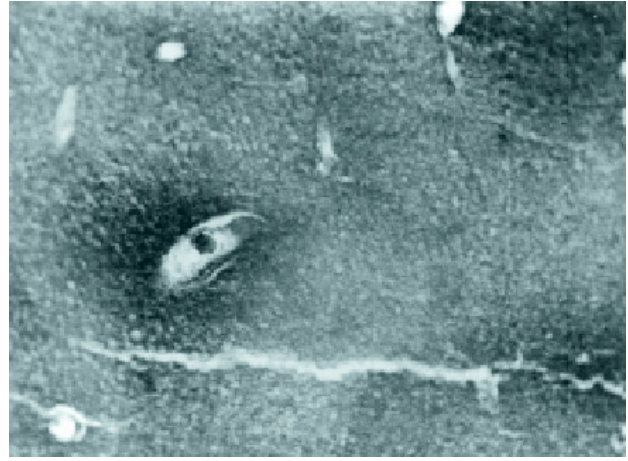
and the kidney weights were found to be significant. Gross observation showed enlargement of liver and kidney size and also appeared pale in color. The enlargement might be due to the rodenticide chemical poisoning. This was also reported by (Willam, 1961), according to him swelling is the commonest and caused by bacterial toxin or chemical poison.

In the histology of treated animals, kidney exhibited necrosis, degeneration and accumulation of toxic metabolic debris in the renal glomerular and tubular cortex region (Fig. 2 to 4). In *Mus musculus* after 40-48 hrs exposure to anticoagulant rodenticide bromadiolone, showed the presence of blood in the urine, this may be due to necrosis and degeneration of renal cortex as seen in the histological preparations. Wolf and Carlton (1989) also reported in Swiss albino mouse, occurrence of acute cortical tubular necrosis due to the administration of 2 Bromoethylamine hydrobromide. Buckley (1989) reported degeneration of distal tubules, necrosis and tubular dilatation in





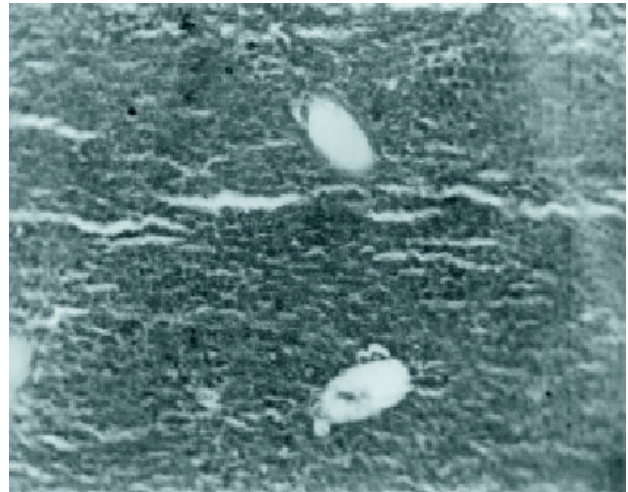
**Fig. 5:** Kidney after 48 hours showing enlargement of cortex, necrosis and degeneration.



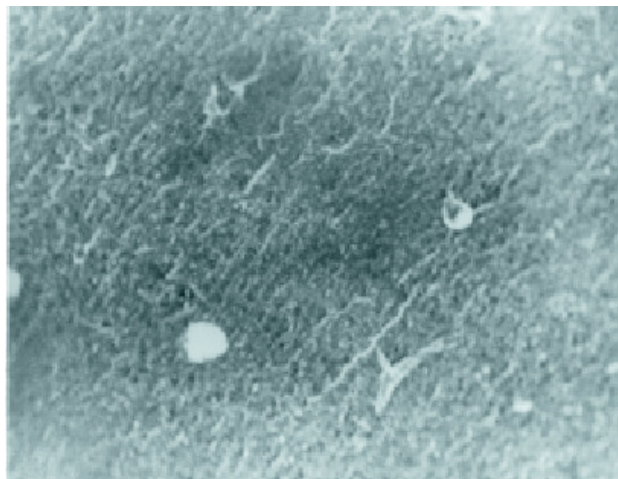
**Fig. 8:** Liver after 12 hours showing feathery degeneration.



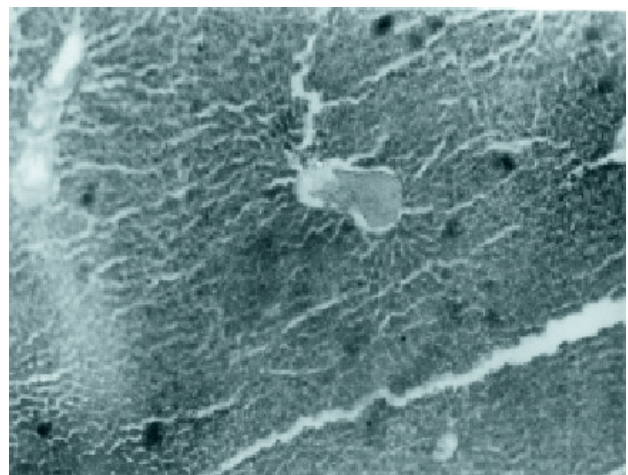
**Fig. 6:** Normal Liver.



**Fig. 9:** Liver after 24 hours showing enlarged nucleus, necrosis and accumulation of toxic debris



**Fig. 7:** Liver after 6 hours showing necrosis and accumulation of toxic debris.



**Fig. 10:** Liver after 48 hours showing heavy damage to hepatocytes

mice when treated with inaphlhol. This renal necrosis could be the influence of anticoagulant rodenticide bromadiolone, which appeared in all animals where the blood was also seen in the faeces of 48 hrs of dosed animals. This is evident that the severity of bromadiolone on kidney degeneration increased with respect to time and dose (Fig. 2 to 4).

In liver sections, there was a clear multifocal cytoplasmic vacuolations, necrosis and accumulation of toxic debris (Fig. 8 and 9). This pathological condition progressively increased from 6, 12, 24 and 48 hrs. This was in conformity with the toxicity studies of C.I. pigment red, conducted at National institute of Environmental health sciences, Birmingham, USA on the liver, kidney, and spleen which were the target tissues in mice, showed haematopoietic cell proliferation in both liver and spleen (EPA, 1976). It was also positive to iron pigments in the spleen.

Apart from resulting renal and hepatic necrosis, the haematological results showed a marked reduction in Hb, RBC, WBC and platelet count in the treated animals. Whereas the WBC count of the treated animal remained high throughout the experimental period accounting to the act of defence mechanism in the body (Table 3). (Kohtrula *et al.*, 1989) reported an increase in WBC when female mice were treated with nivalenol. In *Rattus rattus* when dosed with rocumin 57 showed reduction in Hb, RBC, and prolongation of the bleeding time, i.e, there was an increase in clotting time. There was an increase in leukocyte count and decrease in platelets, which was reported by (Helal *et al.*, 1974), similar results were obtained in the present study.

The anticoagulant rodenticide bromadiolone sharply reduced the blood platelets count and also resulted in degeneration of liver and kidney. From the above experiment it can be clearly shown that the chemical poison present in bromadiolone decreased the excretory capacity of kidney and liver. Prothrombin is a protein, exclusively synthesized by the liver. In case of disease or damage to liver the prothrombin clotting time increases. The main component of bromadiolone is dicumarol. Dicumarol structurally resembles vitamin K. It acts as competitive inhibitor of vitamin K and decreases the synthesis of prothrombin in the liver. The liver plays a major role in nutrition and maintenance of the body. The main function of the liver is the production of bile, maintenance of the blood sugar level, regulation of fat metabolism, detoxification, formation of plasma protein and blood coagulants. Necrosis of the liver reduces the efficiency of the liver. Drugs or poisons may cause necrosis. This effect is seen both on the quantity of the dose and the length of the time that the poison acts. Large doses of poison results in massive necrosis and may be followed by cirrhosis. Thus dicumarol component of anticoagulant rodenticide may have caused internal bleeding.

The most important function of the kidney is to maintain a normal physiological condition of the body. The selective adsorption by tubules of the kidneys is essential for performing this function. Toxic tubular necrosis (Fig. 4 and 5) is mainly caused by exogenous poisons, which interferes with this

function. Ingestion of such chemical substance would result in electrolyte imbalance is constantly associated with acute tubular degeneration (Fig. 4 and 5) which may finally lead to renal failure resulting in the death (Willam, 1961). The chemical poison present in bromadiolone decreases the excretory capacity of the kidney, by causing damage to kidney. As the ultimate result the treated animals are bleeding to death. This is a clear evidence of blood found in excrete of animals.

The only source of fibrinogen is the liver, more over the absorption of vitamin K from the intestine is dependent on the presence of bile salts. For the clotting of blood vitamin K is essential factor. If the vitamin K epoxide cycle is blocked normal clotting of blood at site of haemorrhage is prevented, blood is constantly lost and blood pressure falls eventually leading to death (Willam, 1961).

In case of homeothermic vertebrates, the chemical poisons reduce the haemoglobin percentage, whereas the haematological data of the poikilothermic vertebrates such as fish and frog show the tendency for haemoglobin concentration to be higher when they are exposed to lindane, an organochlorine pesticide. Blood plays a decisive role in the regulation of life process (Hartwing *et al.*, 1981). An organism must be able to keep its blood composition relatively constant under normal conditions. It must also have the ability to change it under extreme conditions of stress, otherwise its survival will be in questions. In the present study, tendency to restore to normal condition is noted in haemoglobin percentage and the RBC count of the treated animals.

## References

- Arora, K.K., S.S. Lal and S. Rani: Studies on newer anticoagulant rodenticides for the control of *Rattus rattus*, *Pestology*, **6**(1), 5-7 (1982).
- Anon: Annual progress report, Central arid zone research institute, Jodhpur, pp. 198 (1983).
- Anon: Summarised results of the researches conducted in India on the evaluation of single dose anticoagulant rodenticides bromadiolone. Pest control (India) Pvt. Ltd., pp. 23-25 (1984).
- Barnett, S.A. and I. Prakash: Rodents of economic importance in India, Arnold - Heinemann New Delhi and London, pp. 175 (1975).
- Buckley, D.: Alteration of total bilirabin lend in rats. *J. Pathobiology*, **33**, 481-490 (1989)
- Chopra, G. and N. Ahmed: Efficiency of bromadiolone against various rodent species. *Rodent news letter*, **7**, 7 (1982).
- Christopher, M.J., M. Balasubramanyam and K.R. Purushotham: Laboratory trials of three anticoagulant rodenticides for use against the Indian field mouse. *Mus booduga*. *J. Hyg. Camb*, **93**, 575-578 (1984).
- Ellerman, J.R.: The Fauna of India, Vol. **3**, 849 (1961).
- Ekambaranathan, M.: Out line of Zoology. Central art press, Madras, 564-566, (1964).
- Engalhardi, J.A., W.W. Carlton and A.H. Rebra: Rubratoxin, B-Mycolixicosis in Swiss ICR Mouse, Report from Dept. of Microbiology and Pathology, Food and Chemicals (1987).
- EPA: Report on "National study on pesticide poisonings programme", Human effect monitoring branch and technical service division office of pesticide program. US. EPA, Washington, DC (1976).

- Gupta, S.P.: Statistical Methods, S. Chand and Sons Publishers, New Delhi (1987).
- Hartwing, D. F. Lamb and G. Robert: Biochemical disturbances in liver injury. *Pharmacological Rev.*, **54(2)**, 145-149 (1981).
- Helal, T. V., L.G. Lomax and R.G. Cole: Haematological studies on Egyptian rodents intoxicated with the anticoagulant rodenticide Racumin. *J. of Vet. Pathol.* **57**, 223-233 (1974).
- Jain, A.P.: Efficiency of supercoid bromadiolone against five rodent pests, *Rodent News Letter*, **4**, 18 (1980).
- Juarez, E.: Chronic effect of five organochlorine insecticides on larvae of *Bufo arenarum*, *Comun. Biol.* **2(4)**, 411-415 (1984).
- Kohtrula, H., G. Nakamura and M.A. Zumiyama: Biochemical basis of carbon tetrachloride induced toxicity. *J. Lab. Toxicol.*, **13**, 35-45 (1989)
- Mathur, R.P. and I. Prakash: Evaluation of Brodifacoum against rodents, *J. Hyg. Comb.* **87**, 179-184 (1981).
- Mathur, R.P. and I. Prakash: Toxicity of coumatetralyl to Gerbils, *Z. News-Zool*, **70**, 257-263 (1983).
- Mathur, R.P. and I. Prakash: Field trails of brodifacoum, Chlorophacinone and coumatetralyl against desert rodents, *Tropical Pest management*, **3**, 58-61(1984).
- Mukthabai, K.: Efficiency of Gophacide to some commensal rodents, *Rodent News Letter*, **4**, 30-31(1980).
- Prakash, I.: Rodents pest management, principles and practices, Central Arid Zone Research institute Monograph, **4**, 1-18 (1976).
- Prakash, I.: Rodent research in India. *J. Nat. Hist. Soc.* **75**, 792 (1978).
- Prakash, I. : Ecology of Indian desert *Gerbil meriones hurrianae*, *News Letters* **3**, 12 (1981).
- Rao, A.M. and I. Prakash : Reproductive ecology of the house mouse *Mus musculus* in desert environment, *Rodent News Letter*, **5**, 1-16 (1982).
- Rana, B.D. and R. P. Mathur: Toxicity and relative acceptability of RH 787 to *Rattus rattus* and *R. meltdade*, *Port Ecs*, **2(331)**, 35 (1980).
- Scurgic, H.R. and A.S. Cooke: Effects of triazine herbicide cyanatryn on aquatic animals, *J. Tox.*, **72**, 135-142 (1979).
- Shamsuddin, V.M. and K.I. Abdulla Koya: Effect of bromadiolone wax cake against *Mus musculus* in Amini Island of Lakshadweep, *Rodent News Letters*, **8**, 8 (1981).
- Soni, B.K. and I. Prakash: Efficiency of brodifacoum against the house mouse *Mus musculus*, *Pest*, **18**, 15-17 (1982).
- Srivastava M.: Scipiroside against field and domestic rats, *Rodent News Letter*, **4**, 19 (1980).
- Subbaiah, K.S. and R.P. Mathus: Potency of bromadiolone against Rodents in India, *Pestology*, **VIII**, 12 (1984).
- Verma A., S. Mitra and G.K. Patnaik: Bioassay trials with few organic biocides on fish *Labeo rohita*, *J. Environ. Hlth.*, **19(2)** 107-115 (1977).
- William Boyd: A Textbook of Pathology. Pub. Lea & Febiger. Philadelphia, (1961).
- Wolf and Carlton: Excretory function of the liver: *Pharmacol. Rev.*, **62(1)**, 111-120 (1989).

---

*Correspondence to :*

**Dr. M. Yogananda**

No. 66, 8<sup>th</sup> A Main, B.T.M. I Stage,  
Bangalore-560 029, Karnataka.

**E-mail :** [moolemath@rediffmail.com](mailto:moolemath@rediffmail.com)

**Tel. :** + 9180-26683697

**Fax :** +91-80-26433570